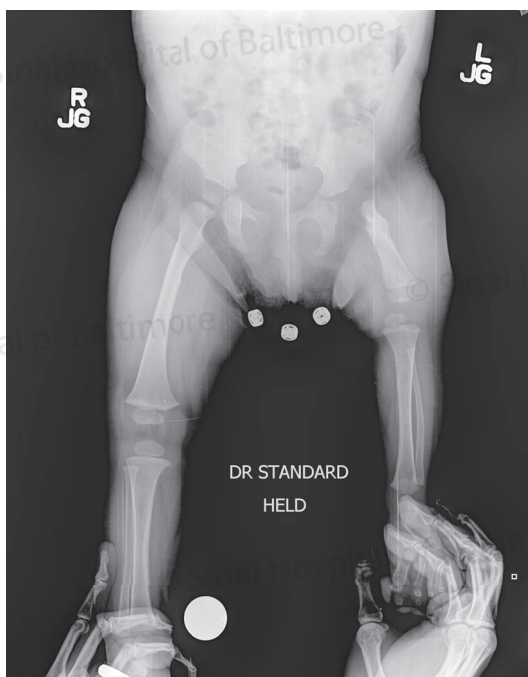
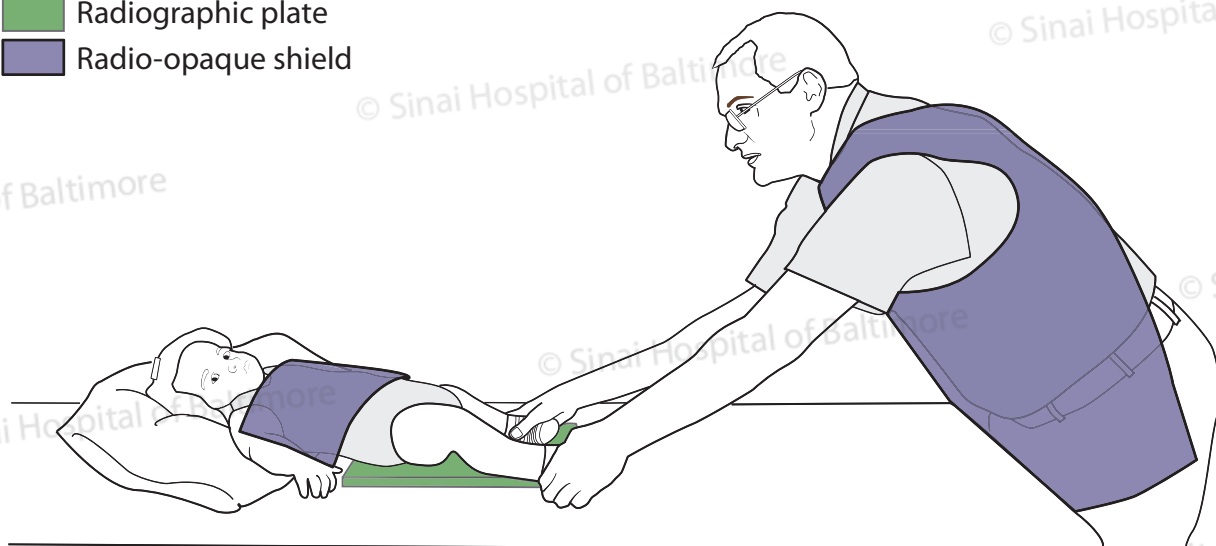
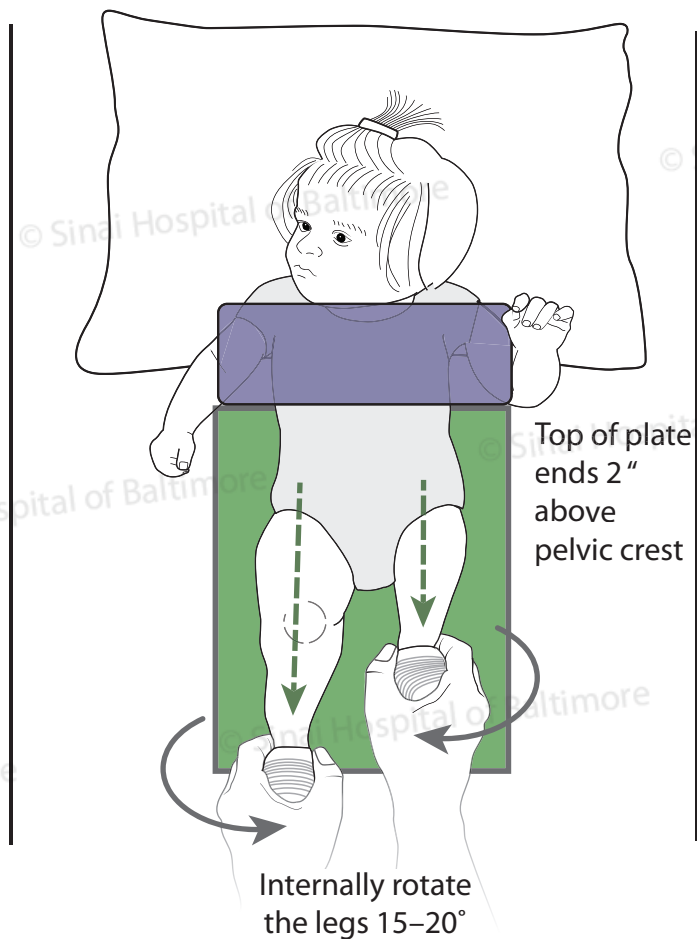


Infant/Toddler Supine AP and Lateral Long Leg X-ray Positions

Infant/Toddler Anteroposterior (AP) Long Leg (Supine) X-ray Position



- Radiographic plate
- Radio-opaque shield



Infant/Toddler
Lateral Long Leg X-ray Position

