

# Perthes Perspective: An Approach to Treatment

**Shawn C. Standard, M.D.**

Perthes is a very confusing disease for the patient and the family. Unfortunately, doctors present a variety of different options and opinions about this disease. The following is my personal perspective on Perthes disease.

## FACTORS THAT AFFECT PERTHES DISEASE

The factors that affect the final outcome are the age of the patient, sex of the patient, the range of motion of the affected hip joint, the amount of necrosis (dead bone) or involvement of the femoral head, the stage of the disease process, and x-ray evidence of “containment.” These factors can help predict the likelihood of a poor or good outcome. With this information, the correct treatment can be selected from the various options.

### Age of the Patient

The younger the patient, the better the outcome is in Perthes disease. A better outcome is defined as a round femoral head (hip ball) in a matching acetabulum (hip cup). However, Perthes disease not only affects the shape of the femoral head; it also significantly affects the growth of the femoral neck (neck of the thigh bone) and femur (thigh bone). Every patient with Perthes disease will have a slowing of the growth in the upper end of the femur (thigh bone). This can result in a clinically significant or problematic leg length discrepancy (more than 2.0 cm or ¾ inch) or a very short femoral neck (neck of the thigh bone). If a young patient has Perthes disease, the disease has more time to slow the growth of the femoral neck and femur before the patient is done growing. As a result, younger patients end up with better hip joints but possibly shorter legs and/or femoral necks. Older patients end up with more hip joint deformity or misshapen femoral heads, but they have a small leg length discrepancy or a relatively normal femoral neck length. The definition of “young” and “old” in Perthes disease is not set in stone. In my practice, I use the following definitions:

Boys: 1–6 years old = young  
7 years old = gray zone  
8–18 years old = old

Girls: 1–5 years old = young  
6 years old = gray zone  
7–18 years old = old

Younger patients have a better chance of a successful outcome with non-operative or minimally invasive procedures (these will be explained below). Older patients require more aggressive treatment, which usually means more complex or involved surgical treatment.

The reasons for the above break down of ages and outcomes have to do with the fact that younger patients have more growth and healing potential than the older patients. The more growth the child has remaining, the more remodeling/healing can occur of the femoral head and the cup that it fits inside. Additional time spent remodeling/healing will allow the femoral head and cup time to repair and to become round.

### Sex of the Patient

Girls fare worse than boys because they become skeletally mature at a younger age than boys. Girls finish growth in the femur (thigh bone) at an average age of 14 years while the femur (thigh bone) in boys is done growing at age 16 years.

### Range of Motion of the Affected Hip Joint

The range of motion of the involved hip joint is the most important factor. This was noted from the very first time this disease was identified by Dr. Arthur Legg and Dr. Jacques Calvé (1910) (Legg-Calvé Perthes disease). Motion is essential to maintain the roundness of the femoral head. During the process of Perthes disease, the inner bone that supports the round cartilaginous femoral head begins to fail as the “dead bone” is absorbed by the body. The loss of this inherent stability of the femoral head creates a situation where the femoral head “softens” and takes on the characteristics of a ball of molding clay or a water balloon.

If the hip motion is lost and the soft femoral head is stuck in one position, then the edges of the hip acetabulum (hip cup) push down on the soft femoral head and change the shape of the hip ball. This femoral head deformation causes a

mismatch in the shape of the hip ball and cup which leads permanent loss of motion, wear and tear on the joint, impingement pain, and eventual arthritis. Impingement pain occurs when the hip no longer moves freely (it gets “stuck”).

On the other hand, if the hip joint motion is maintained, then the soft femoral head is molded like a ball of clay within the hip cup and remains round or spherical. It is important to realize that no matter which treatment is provided, the femoral head shape and size will always change to some degree. Again, the definition of success in Perthes disease is to complete treatment with a round or spherical femoral head that “fits” into the hip cup and provides adequate hip range of motion.

What is considered good or adequate range of motion of the hip is a common question. I consider the following range-of-motion parameters acceptable during the treatment of Perthes disease:

Type of Range of Motion	What Is Considered Good or Adequate
Hip flexion (sitting position of the hip)	more than 90°
Hip extension (standing position of the hip)	full extension (any flexion contracture is not acceptable)
Hip abduction (hip spread position or “snow angel” position)	Involved hip must have at least 50% of the range of motion of the non-involved side. At least 20° of hip abduction must be maintained during the entire process.  Example: If a patient’s non-involved hip abducts or spreads to 60°, then the Perthes hip must abduct or spread to at least 30°.
Hip internal rotation (patient lying on stomach, knees bent to 90°, and legs/feet falling to outside)	at least 20°
Hip external rotation (patient lying on stomach, knees bent to 90°, and legs/feet crossing each other)	at least 20°

### Amount of Necrosis or Involvement of the Femoral Head

This factor is very important factor. Necrosis means that the bone has become dead tissue. By involvement, I mean the percentage of bone in the femoral head that has died. The greater the amount of bone that has died, the poorer the final outcome or the higher the risk of a poor final outcome. If the central, core part of the femoral head is involved, the support structure of the femoral head is very vulnerable. This can be compared to support beams that hold up a roof or ceiling. The more support beams that are “rotten,” the more likely the structure will fail and the roof will collapse.

In terms of involvement, the amount of hip necrosis is usually defined as greater than or less than 50% of the femoral head. This means that if only a very small area of bone necrosis is identified, then the risk of further collapse and problems is very small. Unfortunately, the majority of Perthes cases involve more than 50% of the femoral head.

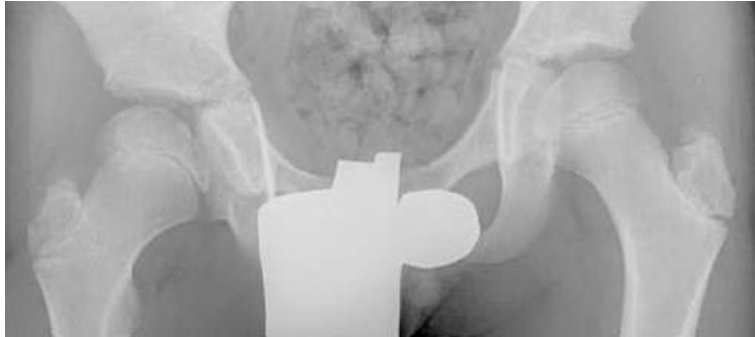### Stage of the Disease Process

I have broken down the Perthes “process” into nine separate stages that each hip with Perthes goes through. Several classification systems already exist in the literature, but the stages provided below were created based on the many patients whom I have treated. Below are x-ray examples of the stages of progression in Perthes disease. The examples below are

from three different patients and provide the best example of each stage. Stage 1 is the only image of that patient. Stages 2 through 6 show the same patient and stages 7 through 9 show the same patient.

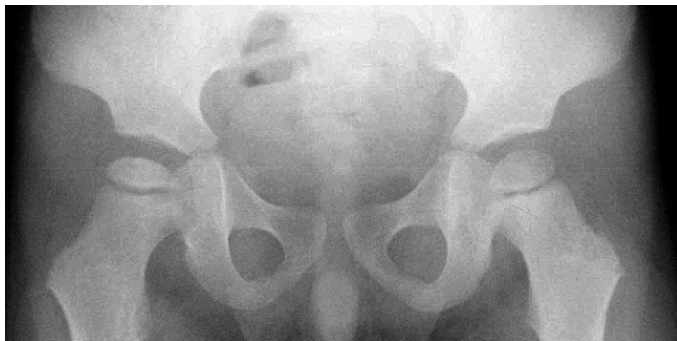- **Stage 1: Precollapse**

No height difference in the core of the femoral head as compared to the opposite side.



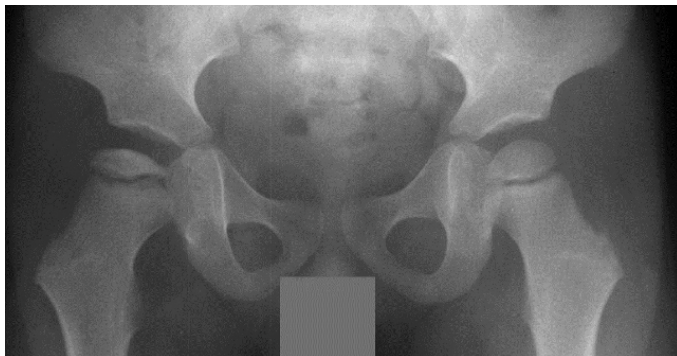
- **Stage 2: Early Collapse**

More than 75% of the height of the core of femoral head as compared to the opposite side.



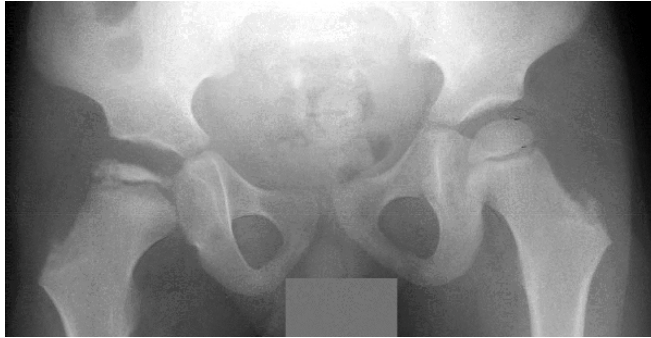- **Stage 3: Mid Collapse**

Between 50% and 75% of the height of the core of femoral head as compared to the opposite side.



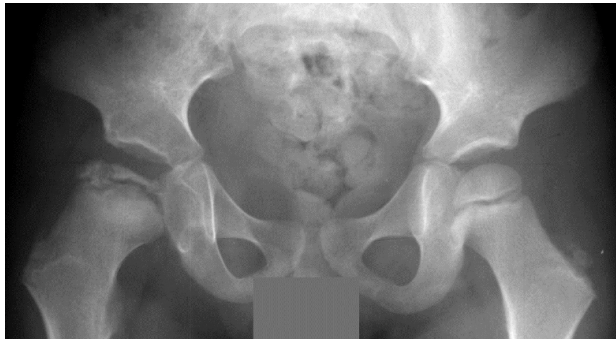- **Stage 4: Late Collapse**

Less than 50% of the height of the core of femoral head as compared to the opposite side.



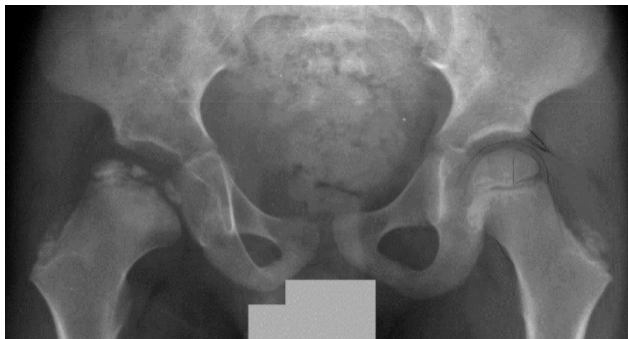
- **Stage 5: Early Fragmentation**

Less than 50% of the femoral head demonstrates fragmentation of the core of bone.



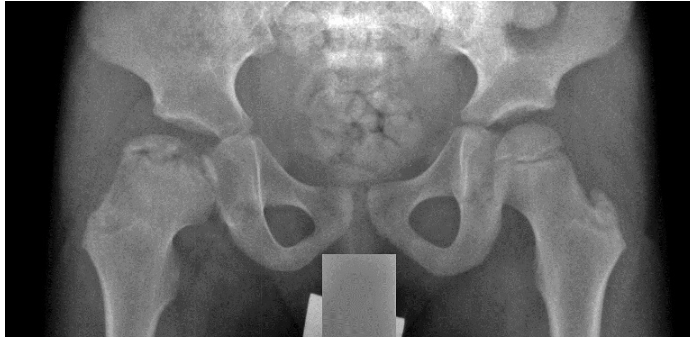
- **Stage 6: Late Fragmentation**

More than 50% of the femoral head demonstrates fragmentation of the core of bone.



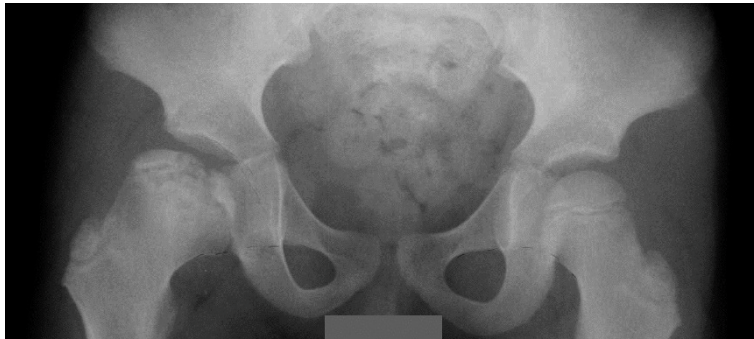- **Stage 7: Early Reconstitution**

Less than 50% of the femoral head demonstrates new bone formation (reconstitution).



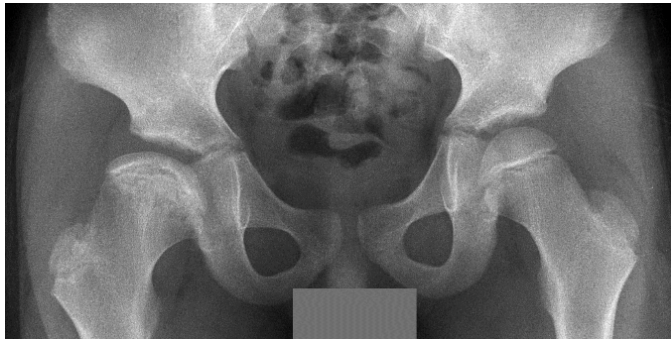- **Stage 8: Late Reconstitution**

More than 50% of the femoral head demonstrates new bone formation.



- **Stage 9: Healed/Reconstituted**

The femoral head demonstrates reconstitution and a solid core of bone.



The purpose of defining the stage of the disease is to give the parents a timeline of where their child is along the “Perthes process.” Please note that although there is a significant variability in this timeline, most Perthes patients complete this process within 18 to 24 months from the start of the hip symptoms.

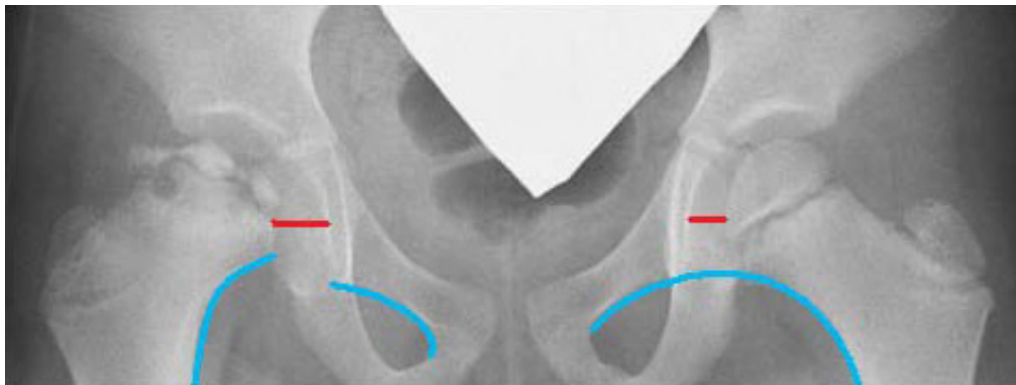
Treatment that is begun before the late fragmentation stage (stage 6) has a more likely to have a successful outcome than treatment begun in the later stages. If the patient is not doing well with a current treatment plan and has loss of hip motion and stiffness, then an aggressive intervention needs to be started before the late fragmentation stage. This stage usually correlates with a change in the shape of the cartilaginous part of the femoral head.



## X-ray Evidence of Hip “Containment”

Hip containment is defined as the ball of the hip joint being properly matched and congruent within the hip cup. When the cartilaginous part of the femoral head (hip ball) collapses, the femoral head will migrate or shift out of the socket. When the femoral head migrates or shifts, it is termed “loss of containment” or “subluxation of the hip joint.” The most consistent way that doctors use to determine whether the hip joint has migrated is to look for a break in Shenton’s line and increased medial joint space on an x-ray.

**Right Hip  
with Perthes**



**Left Hip  
(Normal)**

This x-ray example shows a hip that has lost containment and has migrated outward and upward. The blue line represents Shenton’s line, which should normally be a continuous, unbroken line, as seen on the left hip. Also, the outward or lateral migration of the hip is seen by observing the medial joint space as represented by the red lines. The red line of the right hip is larger than the red line of the left hip. This means the right hip has shifted to the outside or lateral.

## PUTTING IT ALL TOGETHER

I use the above factors to classify the hips into low risk, gray zone, or high risk categories. Once the hip has been classified, then the appropriate treatment plan can be started.

Low risk hips are usually found in younger patients. These hips have good range of motion with intermittent or minimal symptoms. The majority of these hips require non-operative treatment or occasionally minimally invasive treatment (treatments are described in the next section).

The gray zone hips are found in young patients who have more symptoms or loss of hip motion or in older patients who have maintained good hip motion. These hips require close follow-up with aggressive stretching exercises (non-operative treatment) or immediate minimally invasive treatment to expedite the healing process and get the patient back on the right course.

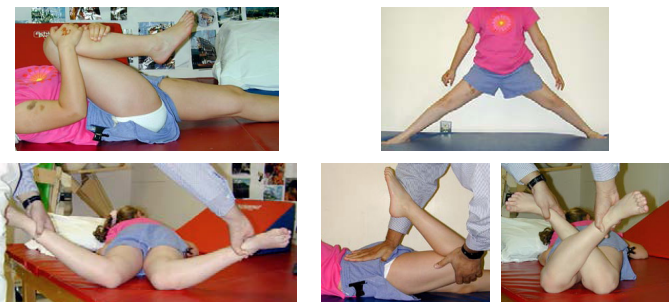
High risk hips are found in older patients who have loss of hip motion or in any patient who presents to my clinic in the later stages of the disease with loss of containment and a stiff hip. These hips require aggressive surgical treatment.

## TREATMENT OPTIONS

I break down the treatment options into non-operative treatment, minimally invasive surgical treatment, and aggressive surgical treatment.

### Non-surgical Treatment

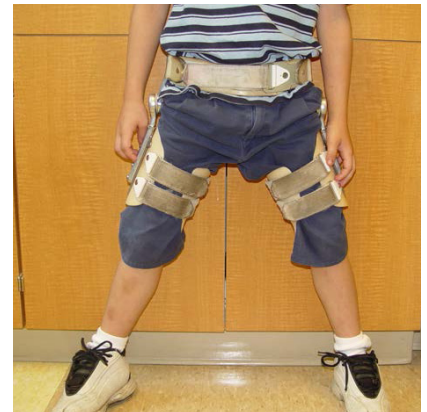This consists of daily stretching exercises performed at home once or twice daily. We call the exercises “Perthes exercises,” and they consist of five basic hip stretches that maintain the essential hip motion that is needed for a successful outcome.



**PERTHES EXERCISES: 2 –3 TIMES PER DAY**

If you would like to have the instructions for these exercises, please e-mail [icll@lifebridgehealth.org](mailto:icll@lifebridgehealth.org). Although the hip stretching exercises are the non-surgical treatment option, these same stretches are a part of all the Perthes treatment plans at my center. No matter what treatment option we use, the hip motion must be restored and maintained to have a successful outcome. In addition to the Perthes exercises that are done at home, patients may also need formal physical therapy. However, this physical therapy should be based on aggressive stretching exercises. We recommend that all patients find a physical therapist who is close to where they live so that they can work with this person throughout the treatment process.

Occasionally, nighttime bracing is used along with the Perthes exercises. The brace is called a Scottish Rite brace (see photo to the right). This brace helps to maintain the range of motion in the abducted (“snow angel”) position.



**SCOTTISH RITE BRACE**

If non-surgical treatment is chosen, the child returns to my clinic for follow-up visits every 4 to 6 weeks during the initial 6 months of the Perthes process. After the critical stages of fragmentation and early healing, the clinic visits become less frequent and occur every 6 to 12 months until growth is completed.

As far as activity limitations, I tell children that normal activity is OK, but they should avoid “big” runs and jumps (they should not jump off the jungle gym or out of a car). As the Perthes process progresses, the activity level can be increased as long as the hip range of motion is maintained and the child does not feel any pain in the hip.

### **Minimally Invasive Surgical Treatment**

- **General Information about Surgical Treatment**

Before surgery, patients must visit their local primary care doctor for medical clearance. The form for medical clearance is called the Preoperative History and Physical Examination Form and it is available at [www.limblength.org/handouts](http://www.limblength.org/handouts). The form needs to be faxed to our office and the family should bring a copy with them when they come to the Rubin Institute. My medical assistant will tell you whether you also need to schedule a preoperative visit at the Rubin Institute before surgery.

- **Arthrogram and Botox Injection**

While the child is under anesthesia, I will conduct a brief evaluation and exam of the hip. With the child asleep and completely relaxed, the true motion of the hip can be determined. At the same time, an arthrogram (injection of a dye into the hip joint) is performed. The dye coats the cartilage and allows the true shape of the cartilaginous part of the femoral head to be seen and examined under live x-ray. A live x-ray means that the x-ray machine captures images of the hip as the hip is moved in all directions. This live x-ray with the dye shows the cartilaginous part of the femoral head while a normal x-ray shows only the bony part at the center of the femoral head.

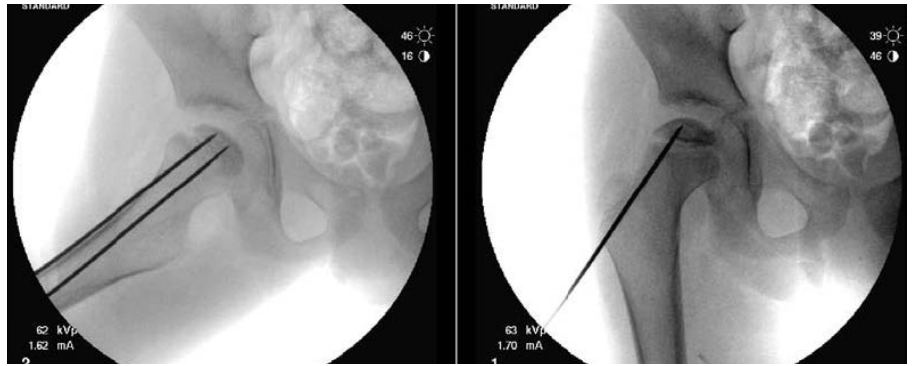
A Botox solution is injected into the inner thigh muscles. This Botox injection will relax the inner thigh muscles and will allow the hip to have a better range of motion in the hip abduction position (snow angel position) during Perthes exercises and during physical therapy. Botox injections are regularly used to treat other muscle conditions where the muscles are too tight. The effects of the Botox injection are not permanent, and full muscle strength returns in a period of about 3 months.

- **Small-Diameter Core Decompression and Injection of Bone Stem Cells into the Femoral Head**

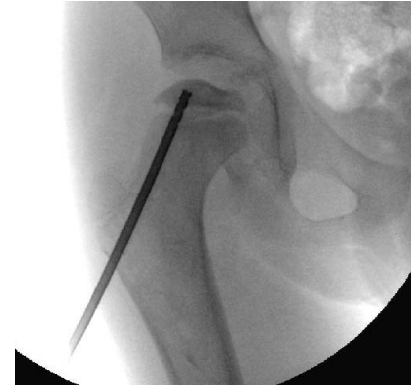
When we perform the arthrogram and Botox injection, we may also decide to simultaneously perform a small-diameter core decompression and inject bone stem cells into the femoral head. During small-diameter core decompression, a wire with a 1 to 2 mm diameter is used to make small holes in the femoral head to stimulate the healing process of the core of bone that is inside the femoral head. The wire is inserted through a small incision and is then guided through the femoral neck into the center for the femoral head (shown in the x-rays on the next page).

The idea behind core decompression is that we make these small holes to stimulate the bone to expedite the healing process and to stimulate the body to make new bone. The main concern of this type of procedure is the

potential harm that could be caused by the wires crossing the growth plate in the upper thigh bone. After a review of 30 cases of Perthes disease treated by small-diameter core decompression, there was no evidence of harm to the growth plate. This same data showed a 70% success rate for this procedure. Success was defined as the hip requiring no further treatment for Perthes disease.



To improve the success rate, I inject bone stem cells (see x-ray to the right) into the femoral head at the same time that I perform the small-diameter core decompression. The bone stem cells are taken from the child and then injected into the femoral head. Since they are taken from the child and are not from another person, they are called autologous bone stem cells. This means the bone stem cells are only from the child with no synthetic or donor cells involved. The bone stem cells are harvested through a simple needle aspiration from the part of the hip bone that is at the waist line (iliac crest). The bone marrow aspiration is then placed in a machine that spins and concentrates the bone stem cells. A bone channel is created in the femoral neck through a small incision but the bone channel does not cross the growth plate. A special needle is then inserted into the core of the femoral head, and the bone stem cells are injected (see x-ray to the right). The goal is to inject the bone stem cells right into the area where the bone tissue has died.



The combination of performing a core decompression to stimulate healing and inserting bone stem cells increases the chances of the bone healing and the symptoms resolving. I have seen a more than 95% success rate when I have combined the small-diameter core decompression with the bone stem cell injection. Again, success is defined as a resolution of the Perthes process with no further surgical treatment and that the femoral head is maintaining a round, spherical shape. Although promising, the procedure and results are preliminary and further follow-up is needed to determine the exact predictability. It is also difficult to determine whether the bone stem cells actually speed up the process of healing. In my experience, the best case scenario is rapid healing of the core of bone that can be seen on an x-ray within 8 to 12 weeks. The worst case scenario is that new bone is not created and collapse of the femoral head continues.

The combined core decompression and stem cell injection is an outpatient procedure (the child does not need to spend the night after surgery in the hospital). The child recovers from the mild soreness within 10 to 14 days. After the procedure, a Scottish Rite brace is worn during the day and at night. Eventually, when the range of motion of the hip is maintained and stabilized, the brace is worn only at night. After the core decompression and stem cell injection, the child returns to the clinic for follow-up visits every 4 to 6 weeks during the 6 months after surgery.

It should be emphasized that the basic stretching exercises are still very important and still need to be performed 2 to 3 times per day after any of the minimally invasive treatments described in this section. If the hip range of motion is not gained and maintained, then the treatment will fail.

## AGGRESSIVE SURGICAL TREATMENT: HIP DISTRACTION

If the hip has not improved or stabilized after more conservative treatments or if the hip is classified as being high risk, then more aggressive treatments are used. There are different types of surgeries that cut the bone of either the pelvis or the



upper femur in order to place the femoral head within the hip cup. These types of operations are called pelvic and femoral osteotomies. Although these procedures may be used as part of the surgical treatment, I rarely use them as the primary surgical treatment. My primary procedure for severe Perthes disease is called hip distraction treatment.

Hip distraction treatment is made up of five phases. During phase 1, I perform soft tissue releases of the contracted hip joint, perform an arthrogram, and apply an external fixator to the hip and upper leg. Phase 1 might also include small-diameter core decompression and bone stem cell injection (described in the “Minimally-Invasive Surgical Treatment” section). During phase 2, the external fixator is used to slowly and gently pull the femoral head 5 to 10 mm away from the cup. This prevents any further pressure or force on the soft femoral head. The external fixator also holds the femoral head in the cup and maintains perfect containment. The external fixator is removed during phase 3. During phase 4, the child wears a brace/pillow, continues Perthes exercises at home and physical therapy sessions, and attends follow-up appointments at the Rubin Institute. The progress with the hip is monitored and maintained during stage 5.

### **Phase 1 of Hip Distraction: Surgery to Release Soft Tissues and Apply the External Fixator**

The surgery is performed under general anesthesia and lasts 3 to 4 hours. While the child is under the effects of anesthesia, an epidural catheter is placed in the lower back. After surgery, medication is given through the epidural catheter to control pain.

The surgery consists of soft tissue releases (tendon releases) in the groin and inner thigh, an arthrogram of the hip joint, and the application of an external fixator device. In some cases, a small-diameter core decompression and injection of bone stem cells into the femoral head will also be performed (these procedures are described in the “Minimally-Invasive Surgical Treatment” section).

Two soft tissue releases are performed to allow the hip joint to become more mobile so that the femoral head can be placed into the proper position inside the cup before the external fixator is applied. An incision is made in the groin that is approximately 1 inch long. This incision is for the release (tenotomy) of the iliopsoas tendon. Another ¼ inch incision is made on the upper inner thigh. The inner thigh muscles are released (tenotomy) through this incision.


After the soft tissue releases are completed, the small-diameter core decompression and injection of bone stem cells might be performed. Then the arthrogram is performed to provide a record of the shape of the hip before the treatment (the arthrogram procedure is described in the “Minimally-Invasive Surgical Treatment” section).

The hip is placed into full extension and approximately 20° of abduction (hip spread position) with the knee cap pointing forward. Then the external fixator is applied. This device consists of three pins above and below the hip joint. The pins are placed through the skin with very small incisions and inserted into the bone. This pin fixation allows for a very stable anchoring point for the external fixator. The external fixator contains a hinge that allows for hip flexion (sitting position) and extension (standing position). The hip joint motion is essential for cartilage healing. During the 4 months that the external fixator is in place, all other motions are restricted.

### **Phase 2 of Hip Distraction: Using the External Fixator to Distract and to Stretch the Hip**

#### **• Immediately after Surgery**

After the external fixator is applied, the child usually stays in the hospital for 3 to 5 days. Medication is given through the epidural catheter to control pain for at least the first 2 or 3 days after surgery. This allows child to immediately start physical therapy with minimal to mild discomfort. The child may also be given valium because it is an excellent muscle relaxant and reduces the muscle spasms, which can be as problematic as the pain. During physical



therapy, the child will start range of motion exercises for the hip and knee. The child will learn to walk with either a walker or crutches with 50% weight bearing allowed on the affected hip. The physical therapist will also teach the child to transfer safely in and out of the bed, wheelchair, and toilet. We will order the child a wheelchair that reclines before the child is released from the hospital.

- **Distracting the Hip**

For the first two weeks after surgery (approximately), the patient and/or the family will distract the hip. The external fixator has a part called a distractor (see the labeled photo of the external fixator), which is adjusted by turning the hex screw  $\frac{1}{4}$  turn twice a day (for a total of  $\frac{1}{2}$  mm per day). Each “turn” gently pulls the hip joint apart. When the femoral head is pulled slightly away from the cup, it is called joint distraction. Joint distraction allows the hip to be free of any force or pressure that could compress the delicate cartilage. It also encourages the cartilage to heal and grow into a more spherical shape. The child remains 50% weight bearing on the affected leg during the 4 months that the external fixator is worn.

- **Stretching and Extending the Hip**

The hip must be stretched and extended every day and night during the entire 4 months that the external fixator is in place. This is done by using a part of the external fixator called the extension bar (see the labeled photo of the external fixator). This adjustable and removable bar maintains full hip extension, which is essential to the treatment. When this bar is in place, the hip is locked in a straight, extended position and no motion can occur. During the 4 months that the external fixator is applied, the bar is placed onto the fixator once or twice during the day for approximately 30 to 45 minutes. The extension bar is also placed every night and worn all night. The bar can be removed during the remaining daytime hours and during physical therapy. If you find that the hip does not want to extend fully because it is too tight, the extension bar can be placed onto the fixator when the hip is slightly bent. Then you can slowly straighten and extend the hip by turning the adjustable nut until the hip is complete straight (fully extended).

- **After Being Released from the Hospital: Physical Therapy**

After being released, the child will continue physical therapy 5 times per week during the distraction period (first 2 weeks after surgery). Typically, one hour of physical therapy will be in the pool and one hour will be outside of the pool. Physical therapy is essential since the motion of the hip joint is the key to success in Perthes disease. After the distraction stage, most patients return home and attend physical therapy sessions near their home. Once the distraction has been completed, physical therapy can be reduced to 2 to 3 sessions per week if the child has good hip and knee motion.

- **After Being Released from the Hospital: Follow-up Appointments at the Rubin Institute**

The majority of our patients at the Rubin Institute for Advanced Orthopedics come from out of town. It is helpful if you have a primary care doctor or an orthopedic surgeon near your home for medical emergencies (which are very rare). However, if surgery is performed at our institute, we insist that the child return to our institute for follow-up appointments to ensure a successful and safe outcome. The appointment consists of conducting a physical examination, reviewing the physical therapy progress reports, and taking x-rays. A follow-up appointment is normally scheduled 2 weeks after the external fixator is applied. Usually, by this appointment, the child has already completed the distraction stage. Six weeks after the external fixator is applied, an x-ray of the hip is taken at a local doctor's office and sent to the Rubin Institute. If the maintenance of the external fixator and the physical therapy are both going well, then x-rays will be taken every 6 weeks and sent to the Rubin Institute for evaluation until the external fixator is removed. However, if any problems occur with the external fixator or during physical therapy, then the patient and family return for an appointment. The office will talk to you about having the child measured for a Scottish Rite brace, which will need to be created and customized before the external fixator removal.

### **Phase 3 of Hip Distraction: External Fixator Removal**

Four months after surgery, the external fixator is removed during an outpatient surgery at the Rubin Institute (the child does not spend the night after surgery in the hospital). The removal cannot be performed by a local orthopedic surgeon. The external fixator removal surgery consists of removing the external fixator and pins, performing a hip arthrogram (explained

above), injecting a Botox solution into the inner thigh muscles, and releasing tissue around each pin site to allow the pin sites to have a flattened appearance when they heal.

#### **Phase 4 of Hip Distraction: Wearing a Brace/Pillow, Continuing Physical Therapy and Daily Perthes Exercises, and Attending Follow-Up Appointments at the Rubin Institute**

- **Wearing a Brace/Pillow**

After the external fixator is removed, a Scottish Rite brace or a special abduction pillow with Velcro straps is worn by the patient. The child will be able to walk and to sit while wearing the brace/pillow. This brace/pillow is worn full time for 4 weeks. “Full time” means that the brace/pillow should be worn 24 hours a day unless the child is in physical therapy or exercising, swimming, bathing, or riding a bike. The brace/pillow encourages the legs to remain in semi-spread position of 20°. This is the best position for the hip during this stage of the treatment. The brace is hinged, which allows the child to bend and straighten the hip. Four weeks after the removal surgery, the child will start wearing the brace/pillow only at night and will continue to do this for the next 3 to 6 months.

- **Attending Physical Therapy Sessions and Continuing Daily Perthes Exercises**

After the external fixator is removed, the physical therapy and home exercise program is essential. The child attends five physical therapy sessions per week immediately after the external fixator is removed. The home exercise program consists of the five stretches that make up the “Perthes exercises” (as shown in the “Non-surgical Treatment Options” section). These stretches are the true secret to success. The exercises are performed 2 to 3 times every day for the first 6 months after the external fixator is removed. Depending on the child’s progress, the physical therapy will eventually be decreased to only 2 to 3 sessions per week, but the child still needs to perform the Perthes exercises consistently 2 to 3 times every day. During the 6 weeks after the removal surgery, the child is allowed to put weight on the affected leg until he or she achieves full weight bearing.

- **Attending Follow-Up Appointments at the Rubin Institute**

The child and family will need to return to the Rubin Institute for a follow-up appointment 6 weeks after the external fixator is removed. After that appointment, additional follow-up appointments will occur every 2 to 3 months (depending on the child’s progress) for the first year after the external fixator was applied so that we can monitor the hip.

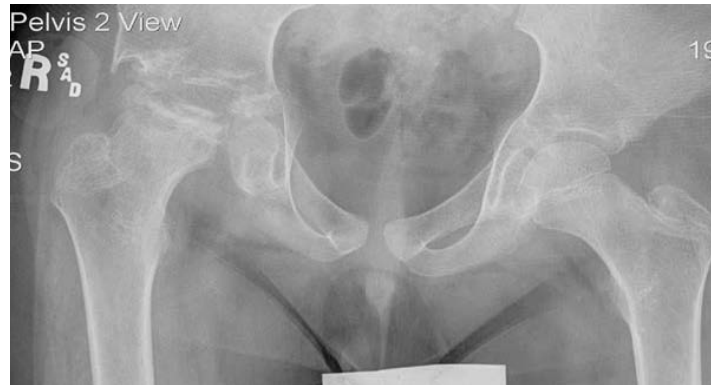#### **Phase 5 of Hip Distraction: Monitor and Maintain Progress**

Our goal is that 6 to 8 months after the external fixator is applied, the child will no longer use the brace/pillow at night and will be able to participate in all physical activities. The Perthes exercises need to be performed daily, but they need to be done only once a day. Most patients ask how long they will be required to continue the Perthes exercises. My standard answer is that the Perthes exercises continue until they graduate from high school. Although a lighthearted response, the truth is that the patients who have excellent outcomes (even if the shape of the femoral head is not ideal) are the patients with excellent hip motion. In Perthes disease, hip motion equals success. Success means that child is not in pain and can return to all previous activities.

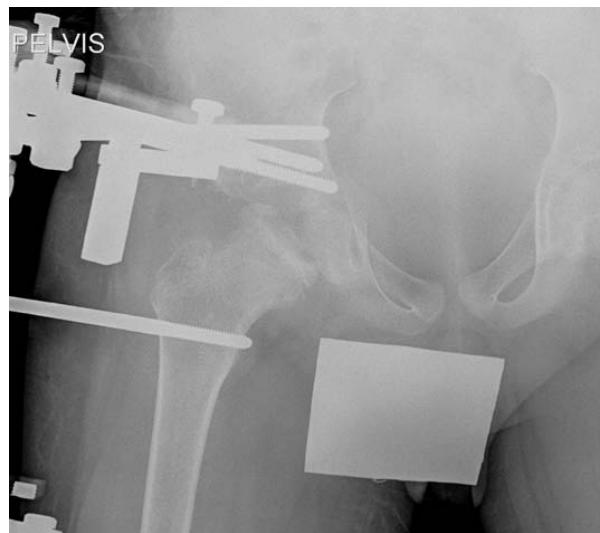When more than a year has passed since the external fixator was applied, the number of office appointments per year at the Rubin Institute decreases to only one appointment every 6 to 12 months until the child is approximately 18 years old. These appointments allow me to monitor the hip growth and hip range of motion. The appointments also give me the opportunity to remind (bug!) the child about the importance of the Perthes exercises and to assess the final shape of the femoral head at the end of growth.

## EXAMPLE OF HIP DISTRACTION TREATMENT

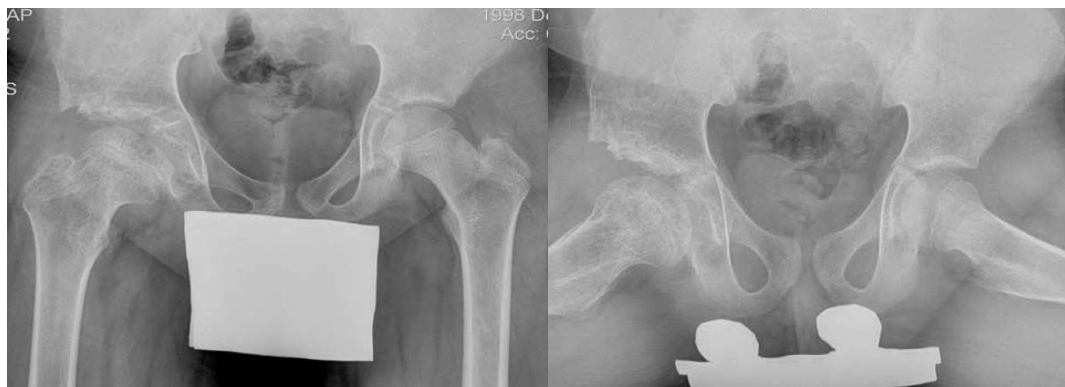Eleven-year-old boy with late-onset Perthes disease. He previously underwent a shelf procedure at another institution that failed.



X-ray shows the hip during hip distraction. Note that the femoral head is completely contained inside the hip cup.



These x-rays show the hip 1 year after hip distraction treatment. The hip has full range of motion, and boy is not in pain.





## STRATEGIES FOR CHILDREN UNDERGOING HIP DISTRACTION TREATMENT

Most patients who undergo treatment are not from Baltimore, Maryland. There are three main strategic approaches to the logistics behind undergoing hip distraction treatment:

1. **Strongly Recommended Option:** The family and patient come for the surgery and plan to stay in town for additional 2 weeks after being released from the hospital. The child attends physical therapy at Sinai Hospital for these two weeks. This strategy has multiple advantages. First, our therapists have the most experience with the external fixator and the hip distraction treatment. This therapist will be able to educate the child and family so they understand what adequate therapy should look like. The family can also record a video of the therapy so that they can show it to their physical therapist at home. This will be extremely important when the child transitions to a local physical therapist. Our physical therapists can communicate directly with your local physical therapist and explain our protocol. Second, the therapy is performed on site at the Rubin Institute. If there is a medical concern or question, the family simply comes upstairs and can be evaluated by the physician or physician assistant in a timely manner. It is important to have access to our physicians and our physician assistants immediately after you are released from the hospital with the external fixator. You will have many questions as to what is normal or what is to be expected. Staying in the area for the first week or two after you are released from the hospital will give you time to adjust to life with an external fixator and will allow us to closely monitor the treatment. You will also be in town for your first follow-up appointment 2 weeks after surgery. After you return home, the x-ray evaluation and clinic visits remain the same as stated above.
2. The family and child come for the surgery. The child stays in the hospital for 3 to 5 days. After being released from the hospital, the family returns home and the child begins physical therapy with a local therapist. The family and patient come to the Rubin Institute for all required follow-up appointments, external fixator removal surgery, etc.
3. The final strategy is for the patient and family to stay during the entire external fixator treatment time (4 to 5 months). This is usually reserved for families in special circumstances or who are from other countries.

## WHAT HOUSING OPTIONS ARE AVAILABLE?

Several affordable housing options are available and can be used for long-term stays (2 to 6 months for lengthening treatment) or for overnight stays. The Hackerman-Patz House ([www.thehackermanpatzhouse.com](http://www.thehackermanpatzhouse.com)) is an apartment facility across the street from the ICLL. This facility is within walking distance from Sinai Hospital, has handicap accessibility, and offers free parking. Marilyn Richardson coordinates the reservations and planning details. Another facility is the Ronald McDonald House ([www.rmhcbbaltimore.org](http://www.rmhcbbaltimore.org)), which is within driving distance from Sinai Hospital. The Ronald McDonald House provides a shuttle service to the ICLL. Many of my patients find that these facilities provide a supportive, family atmosphere.

## PEOPLE WHO CAN HELP YOU PLAN YOUR TREATMENT STRATEGY

Lee Brady, R.N. – Nurse Educator/Care Coordinator	410-601-9425 or <a href="mailto:vbrady@lifebridgehealth.org">vbrady@lifebridgehealth.org</a>
Marilyn Richardson – Pediatric Liaison	410-601-9533 or <a href="mailto:myrichar@lifebridgehealth.org">myrichar@lifebridgehealth.org</a>
Leslie Hresko – Dr. Standard's Administrative Assistant	410-601-1725 or <a href="mailto:lhresko@lifebridgehealth.org">lhresko@lifebridgehealth.org</a>