

Ahmed I. Hammouda, MD,¹ Vivian L. Szymczuk, MD,² Martin G. Gesheff, BS,³ Janet D. Conway, MD,³ Shawn C. Standard, MD,³ and John E. Herzenberg, MD³

¹Department of Orthopaedic Surgery, Al-Azhar University, Cairo, Egypt; ²University of Illinois College of Medicine at Peoria, Peoria, Illinois, USA; ³International Center for Limb Lengthening, Rubin Institute for Advanced Orthopedics, Sinai Hospital of Baltimore, Baltimore, Maryland, USA

Disclosures: JDC is a consultant for Biomet and Cerament; receives research support from Microbion, CD Diagnostics, and Acelity; receives fellowship support from Biocomposites; and receives royalties from the University of Florida. SCS is a consultant for NuVasive Specialized Orthopedics and receives royalties from NuVasive Specialized Orthopedics and Pega Medical. JEH is a consultant for Orthofix, OrthoPediatrics, NuVasive Specialized Orthopedics, and Smith & Nephew; receives research support from NuVasive Specialized Orthopedics; and is on the editorial board of the World Journal of Orthopaedics. AIH, VLS, and MGG have nothing to disclose.

Introduction

- Limb length discrepancy (LLD) is often accompanied by angular and/or rotational deformity.
- Traditionally, both limb lengthening and deformity correction have been simultaneously achieved using external fixation.¹ However, external fixators have many drawbacks such as pin tract infections, joint contractures, and regenerate bone healing problems.²
- Magnetically-activated, intramedullary (IM) limb lengthening nails are an alternative to external fixation, but they are designed for lengthening only.²⁻⁴
- Our aim was to determine the results of using magnetically-activated limb lengthening nails for simultaneous lower limb acute deformity correction and lengthening.

Methods

- Patients underwent simultaneous acute deformity correction and lengthening with magnetically-activated limb lengthening nails between January 2012 and August 2015.
- Moderate acute deformity correction and lengthening were performed through the same metaphyseal osteotomy site for cases in which the magnitude of deformity was $\leq 15^\circ$.
- 25 patients (10 males, 15 females)
- 29 segments (18 femurs, 11 tibias)
- Mean age: 17 years (range, 8–49 years)
- Etiologies included:
 - Congenital femoral deficiency and/or fibular hemimelia: 14 segments
 - Achondroplasia: 5 segments
 - Post-traumatic deformities: 3 segments
 - Skeletal dysplasia: 3 segments
 - History of clubfoot: 2 segments
 - Marfan syndrome: 1 segment
 - Perthes disease: 1 segment
- Distraction index (DI) was defined as the length achieved in millimeters divided by lengthening duration in days.
- Consolidation index (CI) was defined as the number of days from surgery until consolidation divided by the length of the regenerate in centimeters.

Surgical Technique: Fixator-assisted Nailing for Acute Deformity Correction

- Two 6-mm external fixation pins were inserted: one in the proximal segment and the other in the distal segment. They were inserted in one plane (frontal plane for varus or valgus deformity; sagittal plane for procurvatum or recurvatum deformity) in the optimal position away from the predicted nail path.
- For oblique plane deformity, two additional external fixation pins were inserted in a second plane (Figure 1).
- Rotational deformity was typically controlled using two pins (Figure 2).
- Osteotomy was made via a 1-cm incision at the planned site using multiple drill holes and an osteotome. This was followed by acute deformity correction in all planes. The position was maintained by attaching adjustable monolateral fixator units to the pins and tightening the nuts.
- Eighteen femoral nails were inserted:
 - Antegrade to correct rotational deformities (6 segments).
 - Retrograde to correct distal femoral deformities (12 segments).
- All 11 tibial nails were inserted antegrade.

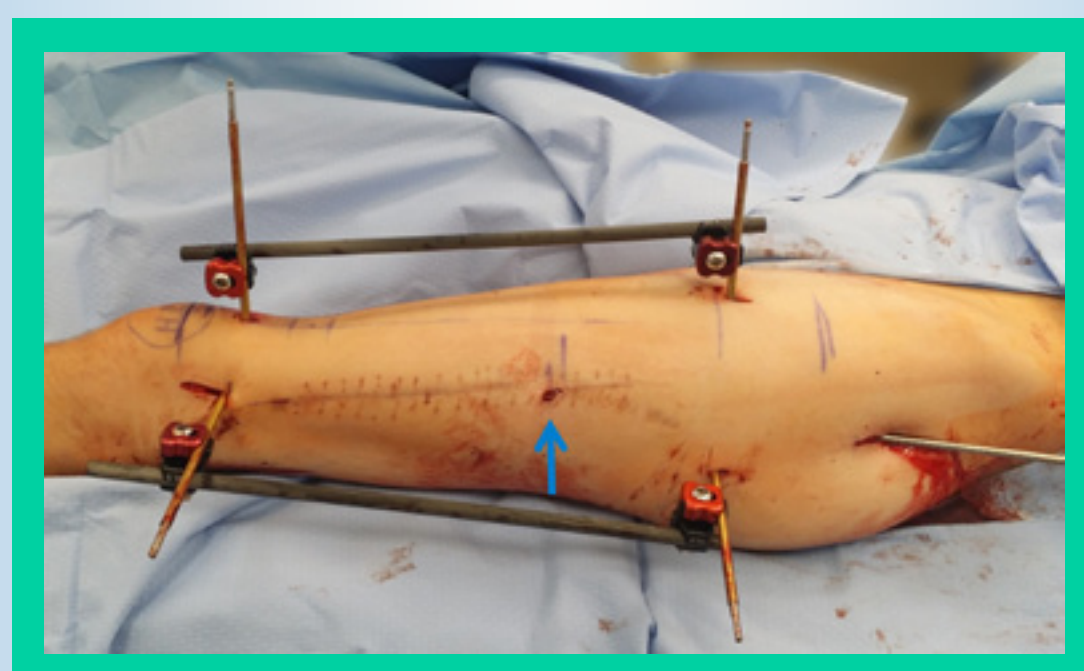


Figure 1. Femoral fixator-assisted nailing technique with planned antegrade insertion of nail to correct two planes of deformity. The blue arrow points to the osteotomy site.

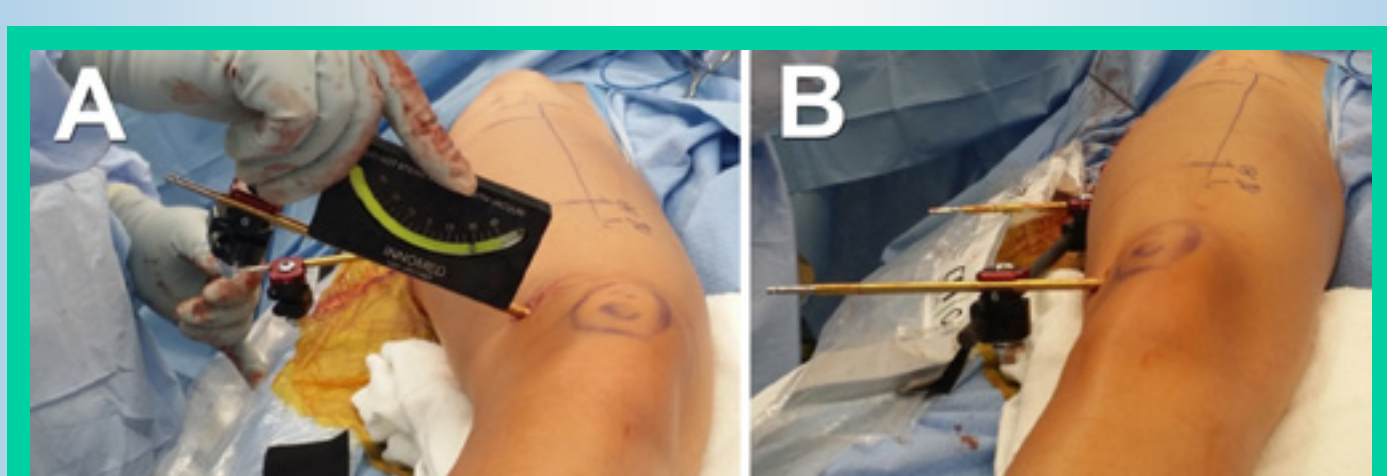


Figure 2. Intraoperative rotational deformity correction. A, Before correction. B, After correction.

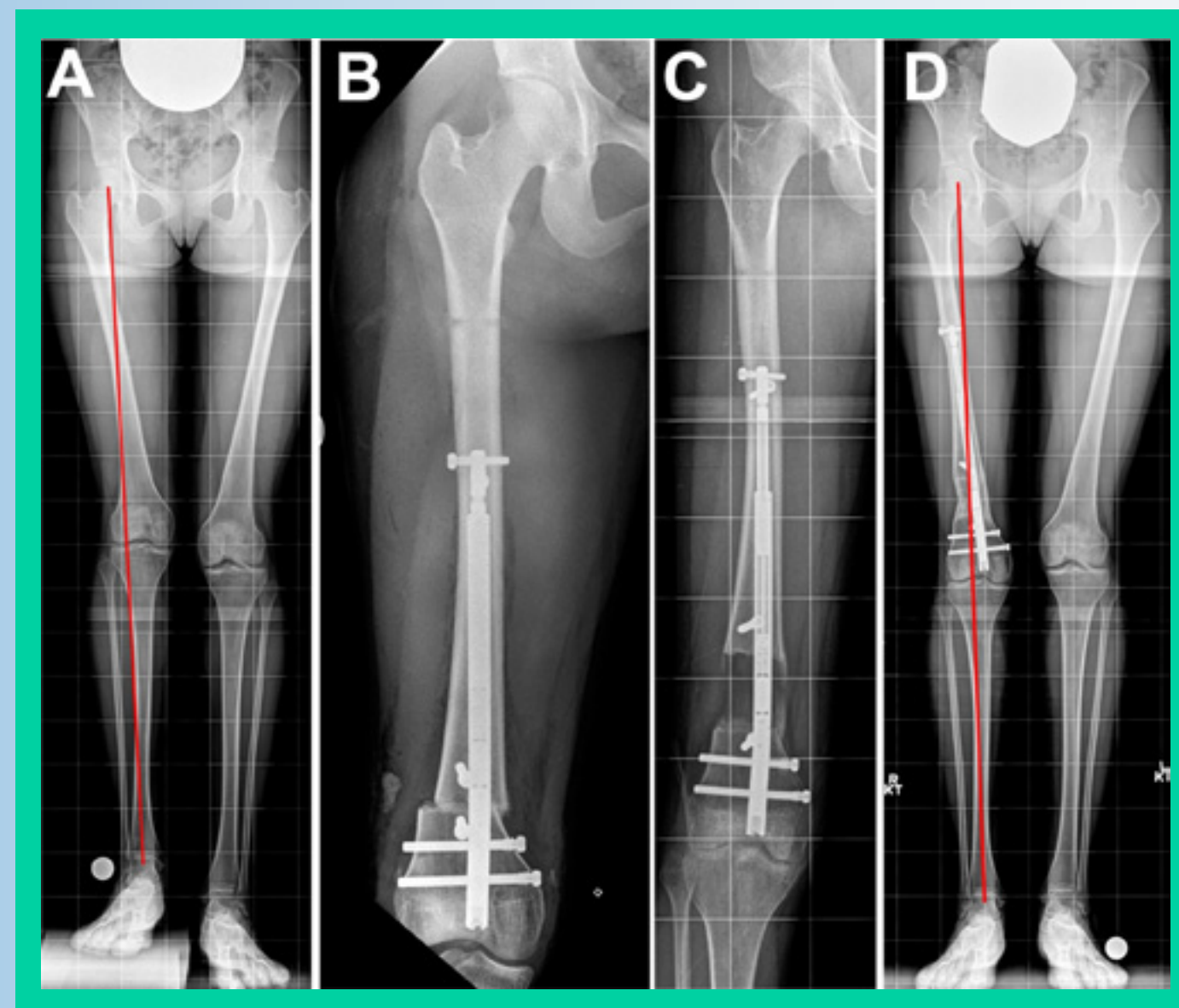


Figure 3. Twenty-year-old female with congenital femoral deficiency of the right limb. A, 4.5-cm femoral discrepancy with 11° distal femoral valgus deformity (lateral MAD). B, Radiograph obtained immediately after retrograde acute deformity correction and insertion of lengthening nail. Two blocking screws help to prevent valgus. C, Radiograph obtained after complete distraction was achieved. D, Radiograph shows regenerate consolidation, equalized limb lengths, and corrected limb alignment.

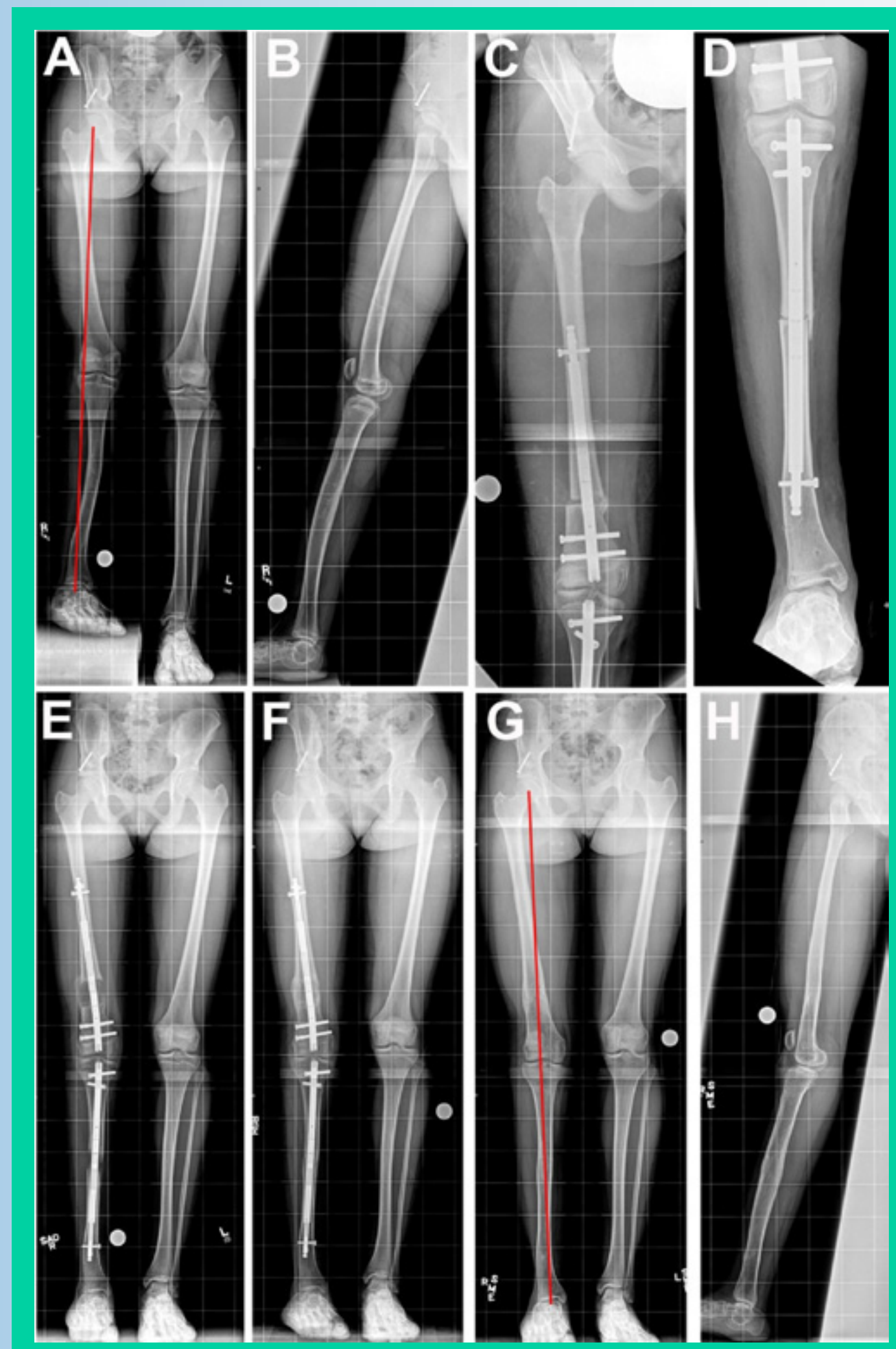


Figure 4. Fourteen-year-old girl with congenital femoral deficiency and fibular hemimelia of the right limb. A and B, AP (A) and lateral (B) view preoperative radiographs show lateral mechanical axis deviation, 3.5-cm femoral discrepancy, and 7° femoral valgus. The patient also has 6-cm tibial discrepancy, 9° tibial valgus, 3° tibial procurvatum, and 10° internal tibial torsion. C and D, Radiographs obtained immediately after acute deformity correction and insertion of lengthening nails into the femur (C) and tibia (D). E, Radiograph obtained after complete distraction. F, Consolidation of the regenerate achieved. G and H, AP (G) and lateral (H) view radiographs obtained after nails removed. Note that the limb alignment has been corrected.

Table 2. Twelve (41%) of 29 segments encountered complications.

No. of Complications	No. Femoral/Tibial Segments	Type of Complication	Treatment
6	5 femurs, 1 tibia	Delayed union	3 segments: rod dynamization and bone marrow stem cell injection or bone graft 2 segments: medical supplements; 1 femur achieved 5 cm of the 6-cm goal 1 segment: Zolendronic acid infusion
2	2 femurs	Knee rotatory subluxation	1 segment: ligament reconstruction 1 segment: physical therapy and discontinuing lengthening (achieved 2.8 cm of the 5-cm goal)
2	1 femur, 1 tibia	Nerve compression symptoms	Nerve decompression
1	1 tibia	Nail failure with premature consolidation	Re-osteotomy and nail exchange
1	1 tibia	Rod migration and resultant valgus deformity due to patient noncompliance (early weight bearing)	Acute deformity correction using fixator-assisted nailing; lengthening nail exchanged for trauma nail

Results

- Mean follow-up: 2.1 years
- Mean preoperative angular deformity (22 segments): 7° (range, 3° – 11°)
- Mean preoperative rotational deformity (13 segments): 18° (range, 10° – 45°)
- All segments achieved the desired deformity correction (Figures 3–6).
- Mean mechanical axis deviation (MAD):
 - Preoperative MAD: 1.3 cm
 - Postoperative MAD: 0.8 cm
- Mean lengthening goal: 4.7 cm (range, 1–8 cm)
- Mean lengthening achieved: 4.6 cm (range, 1–8 cm) (Table 1)
- Twelve (41%) of 29 segments encountered complications (Table 2).

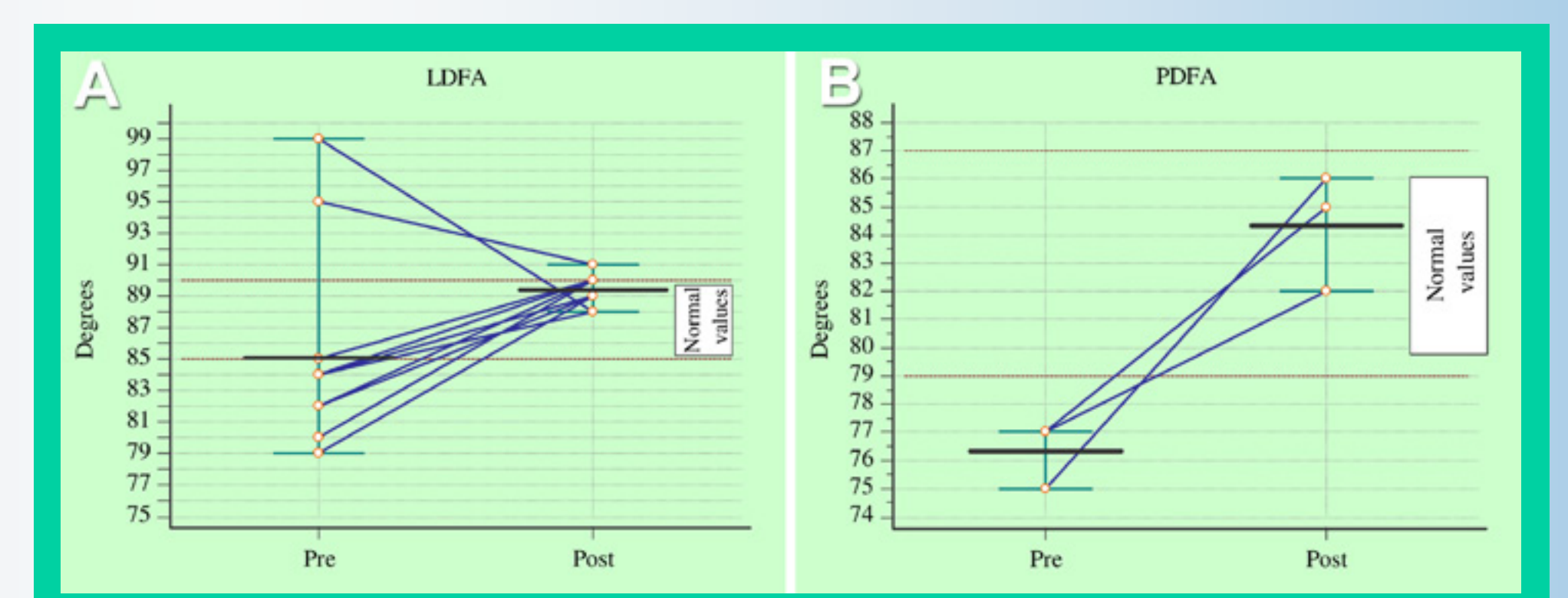


Figure 5. Femoral frontal (A) and sagittal (B) deformity measurements before and after correction. LDFA, lateral distal femoral angle; PDFFA, posterior distal femoral angle.

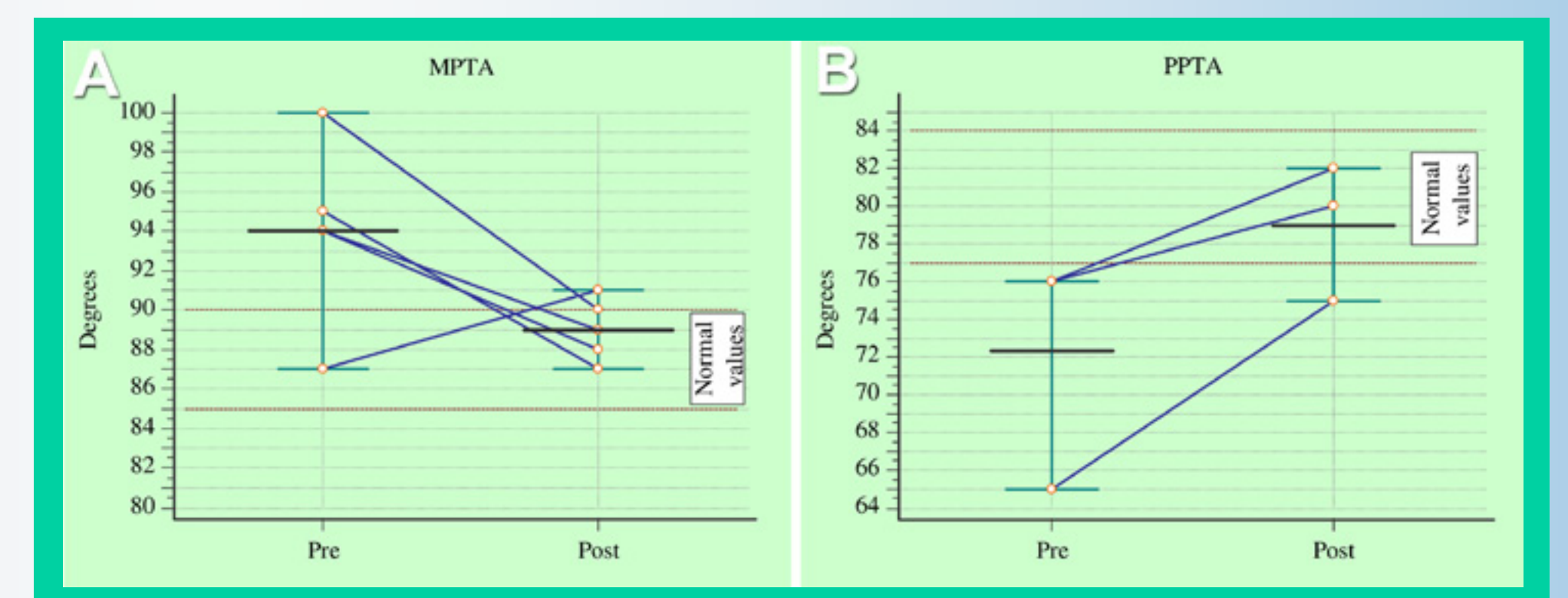


Figure 6. Tibial frontal (A) and sagittal (B) deformity measurements before and after correction. MPTA, medial proximal tibial angle; PPTA, posterior proximal tibial angle.

Table 1. Comparison between femoral and tibial outcomes.

	Femur (n = 18)	Tibia (n = 11)	P value
Length achieved (cm)	5.1 (2.1 – 8)	3.8 (1 – 6.5)	0.04
DI (mm/day)	0.7 (0.4 – 0.9)	0.6 (0.4 – 1.2)	0.78
CI (days/cm)	37.1 (17.3 – 65)	51.6 (24 – 108)	0.08

DI, distraction index; CI, consolidation index

Conclusions

- With preoperative planning and intraoperative fixator-assisted nailing technique, magnetically-activated limb lengthening systems allow for simultaneous acute angular, rotational, or combined deformity correction as well as lengthening.
- One limitation is that the apex of deformity must be located at/near the lengthening osteotomy site.
- It is unclear whether deformities with magnitudes $>15^\circ$ can be accommodated.

References

- Kamegaya M, Shinohara Y, Shinada Y. Limb lengthening and correction of angulation deformity: immediate correction by using a unilateral fixator. *J Pediatr Orthop* 1996;16:477–9.
- Rozbruch SR, Birch JG, Dahl MT, Herzenberg JE. Motorized intramedullary nail for management of limb-length discrepancy and deformity. *J Am Acad Orthop Surg* 2014;22(7):403–9.
- Cole JD, Justin D, Kasparis T, et al. The intramedullary skeletal kinetic distractor (ISKD): first clinical results of a new intramedullary nail for lengthening of the femur and tibia. *Injury* 2001;32(Suppl. 4):SD129–39.
- Guichet J, Deromedis B, Donnan LT, et al. Gradual femoral lengthening with the Albizzia intramedullary nail. *J Bone Joint Surg Am* 2003;85:838–48.